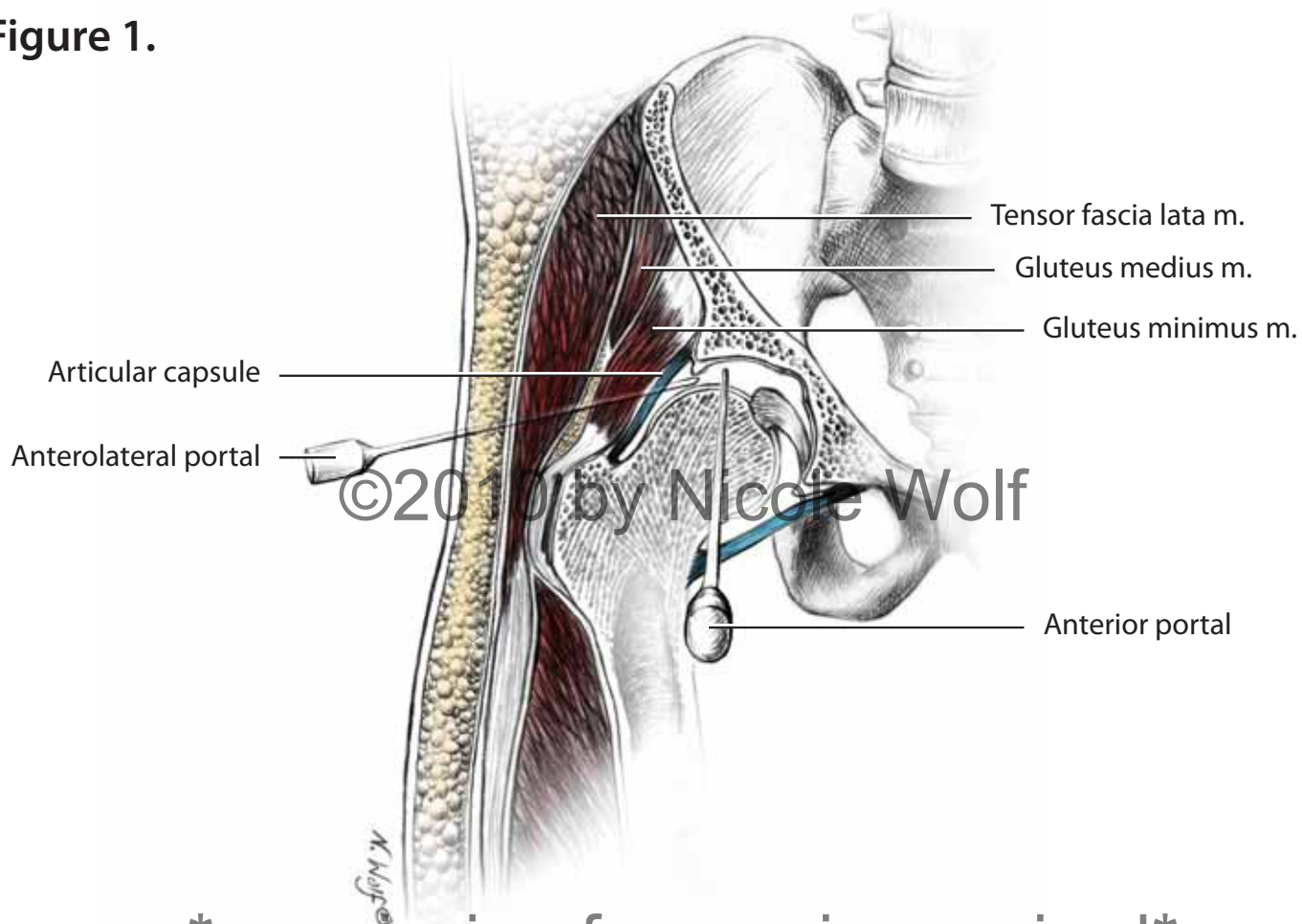


Figure 1.



permission for use is required

Figure 2.

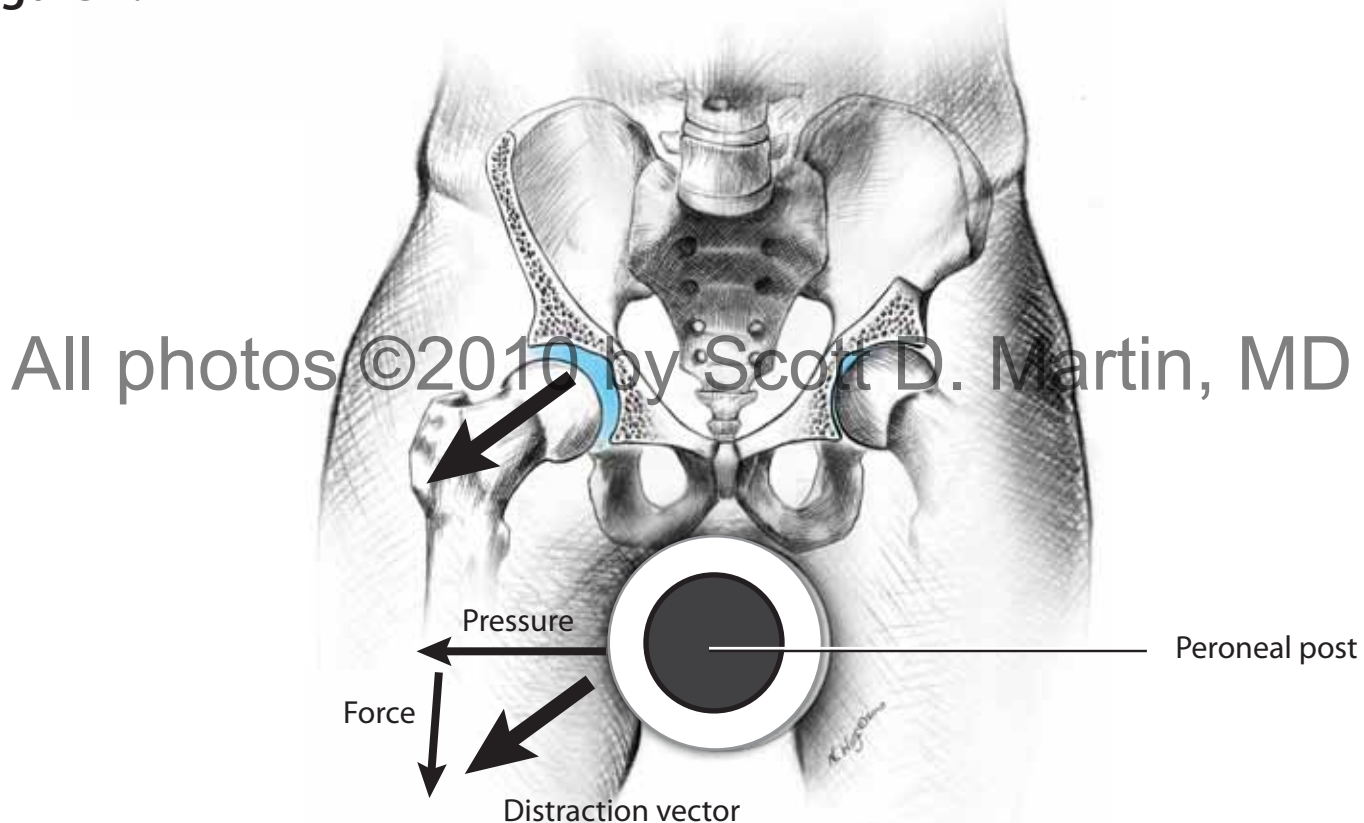


Figure 3.

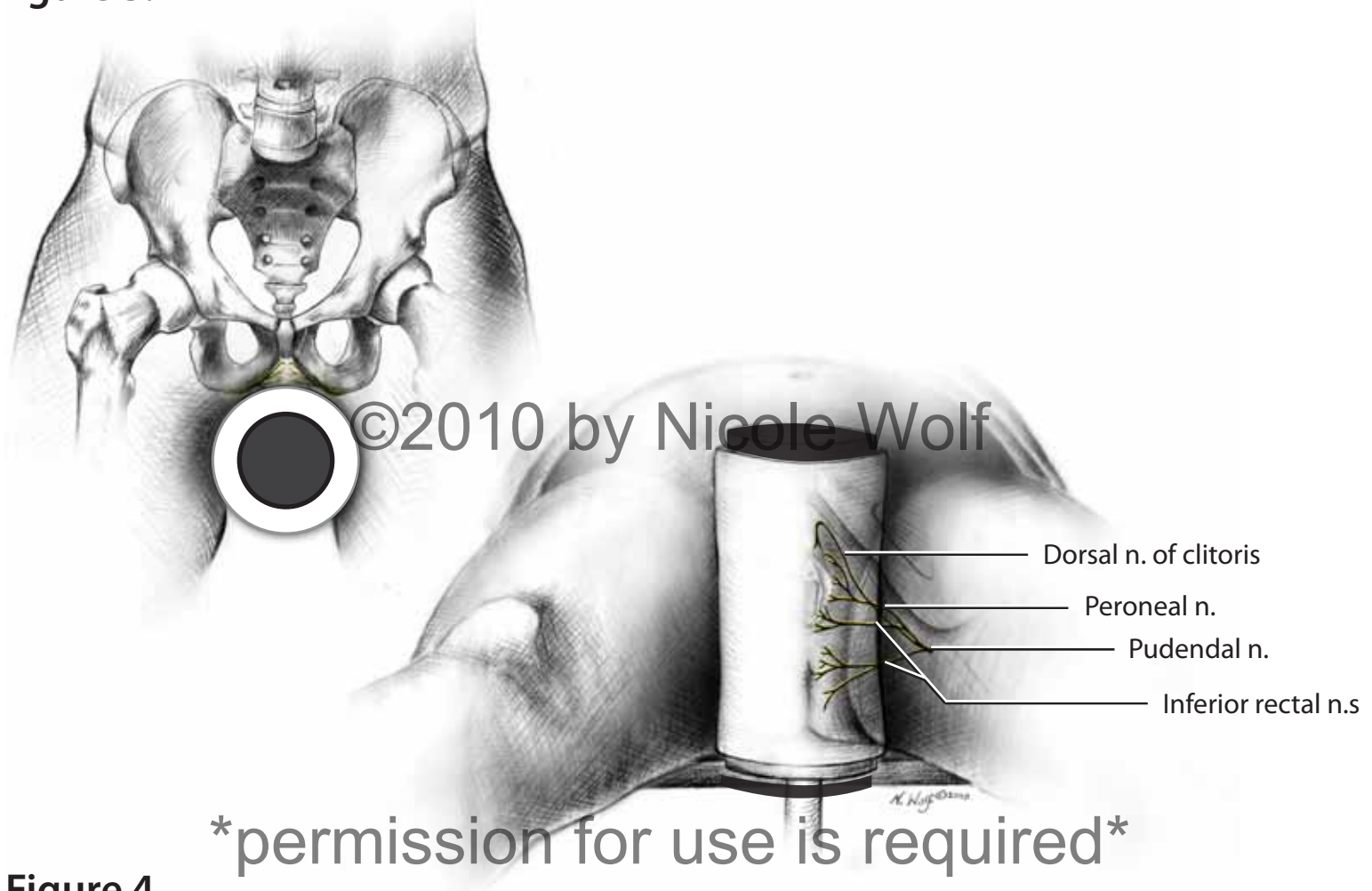
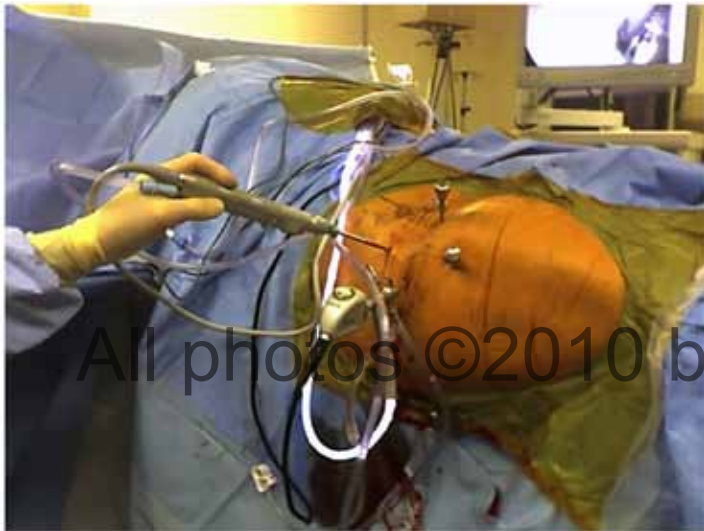

Figure 4.



All photos ©2010 by Scott D. Martin, MD

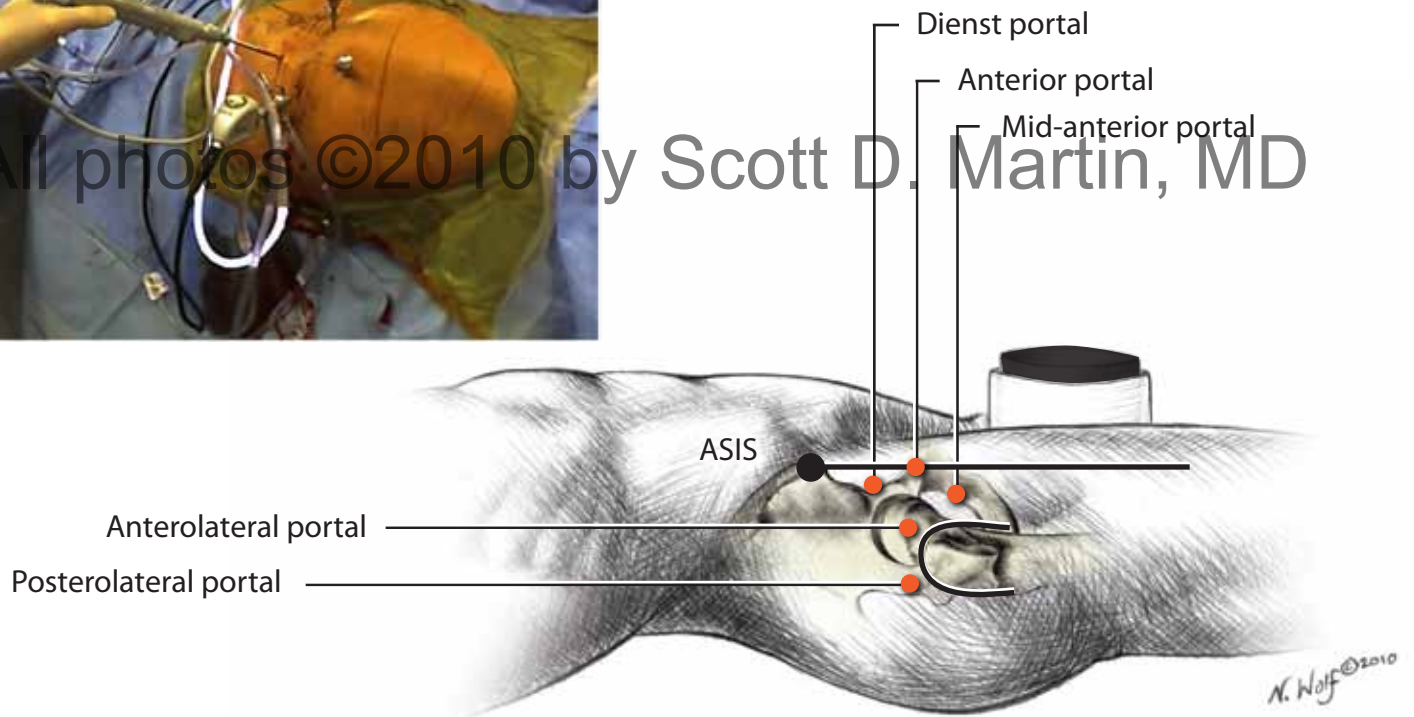
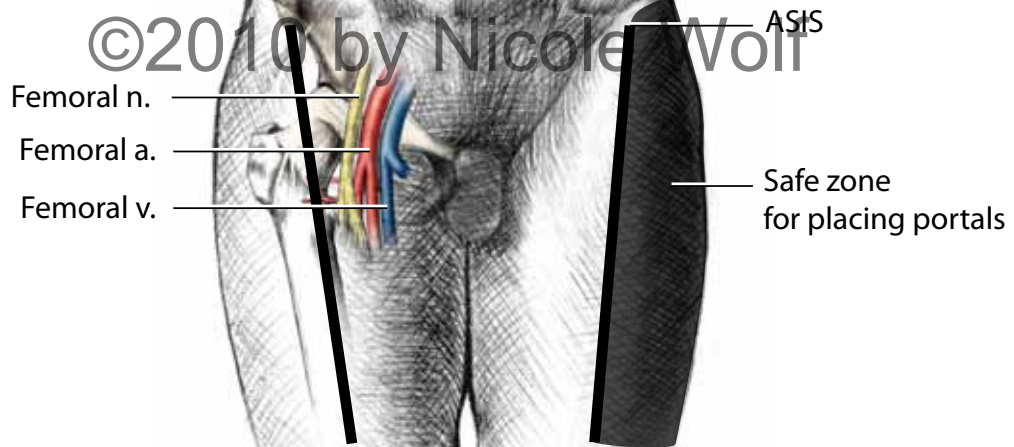


Figure 5.



permission for use is required

Figure 6.

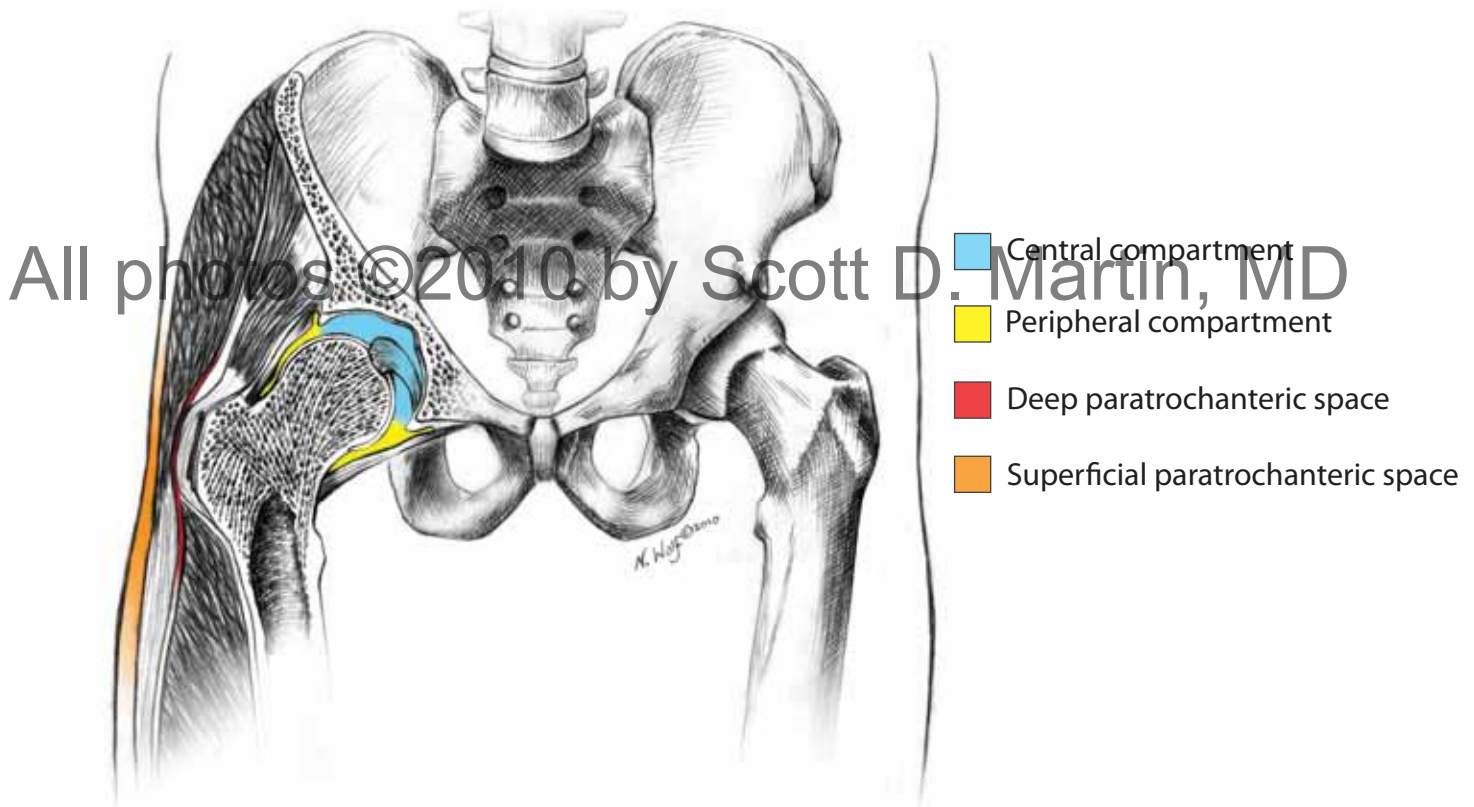


Figure 7.

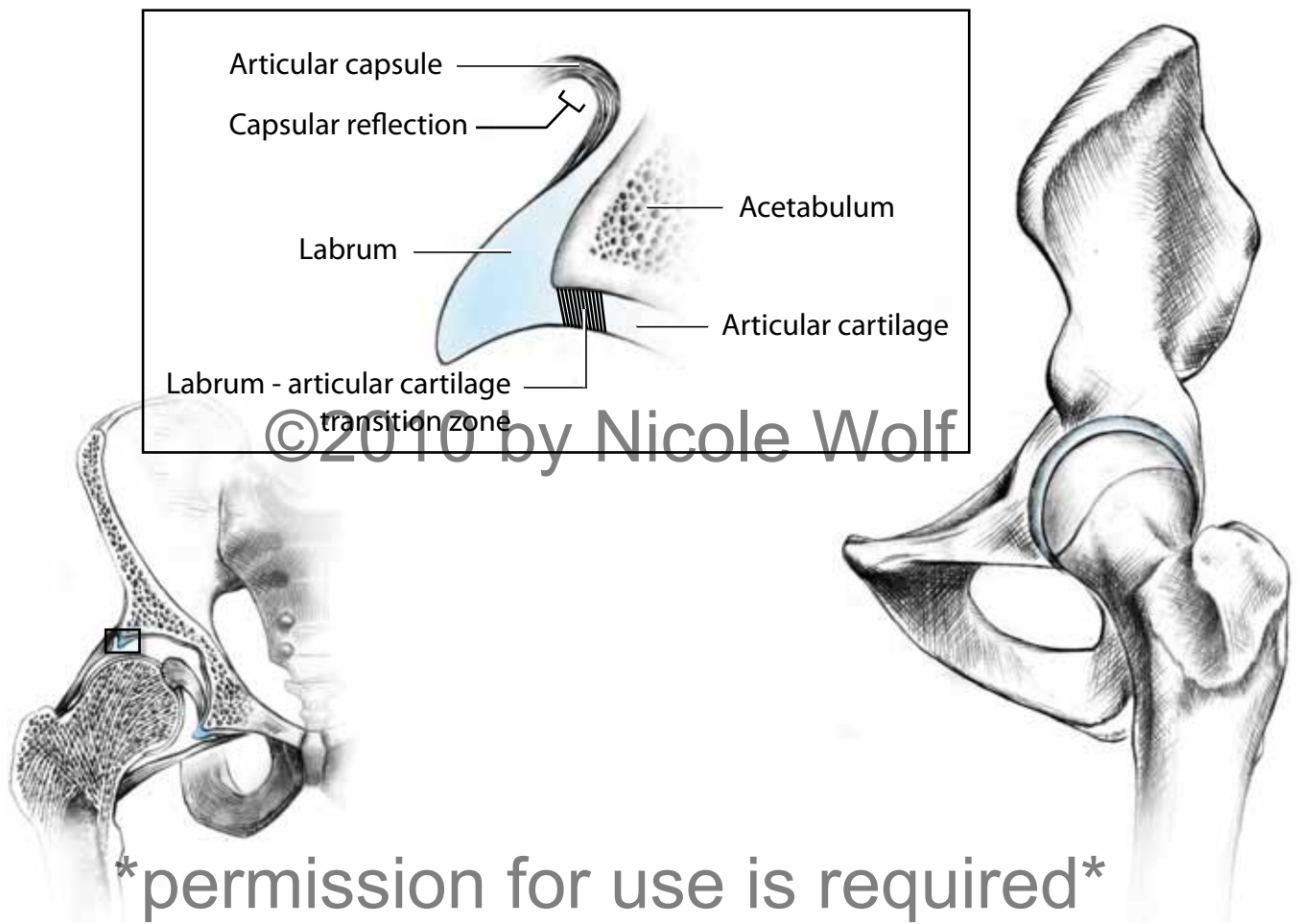
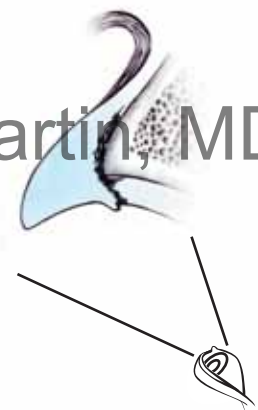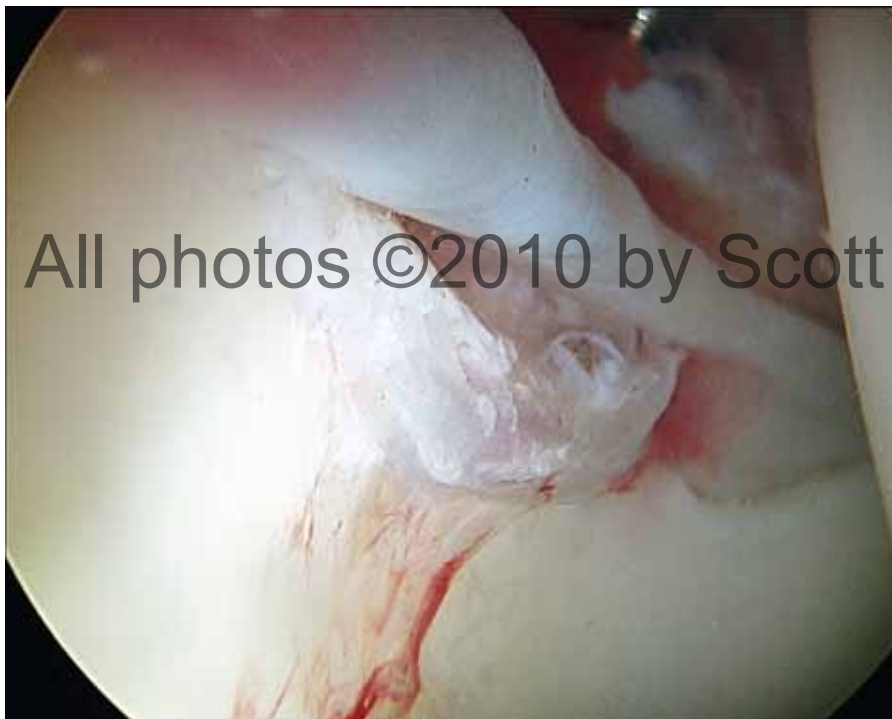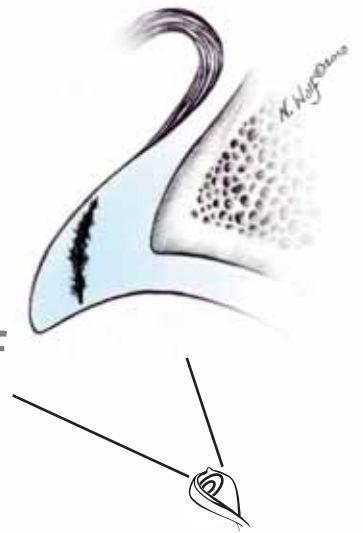


Figure 8a.



Type 1 Tear

Figure 8b.

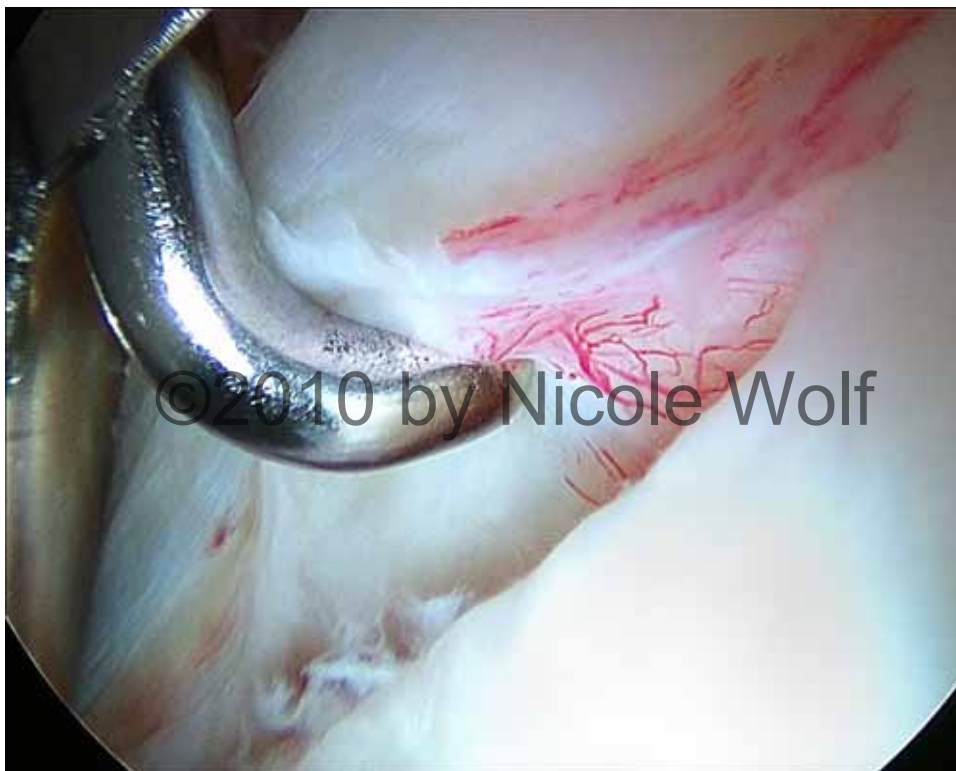

Type 2 Tear

permission for use is required

All photos ©2010 by Scott D. Martin, MD

Figure 9.



permission for use is required

Figure 10.

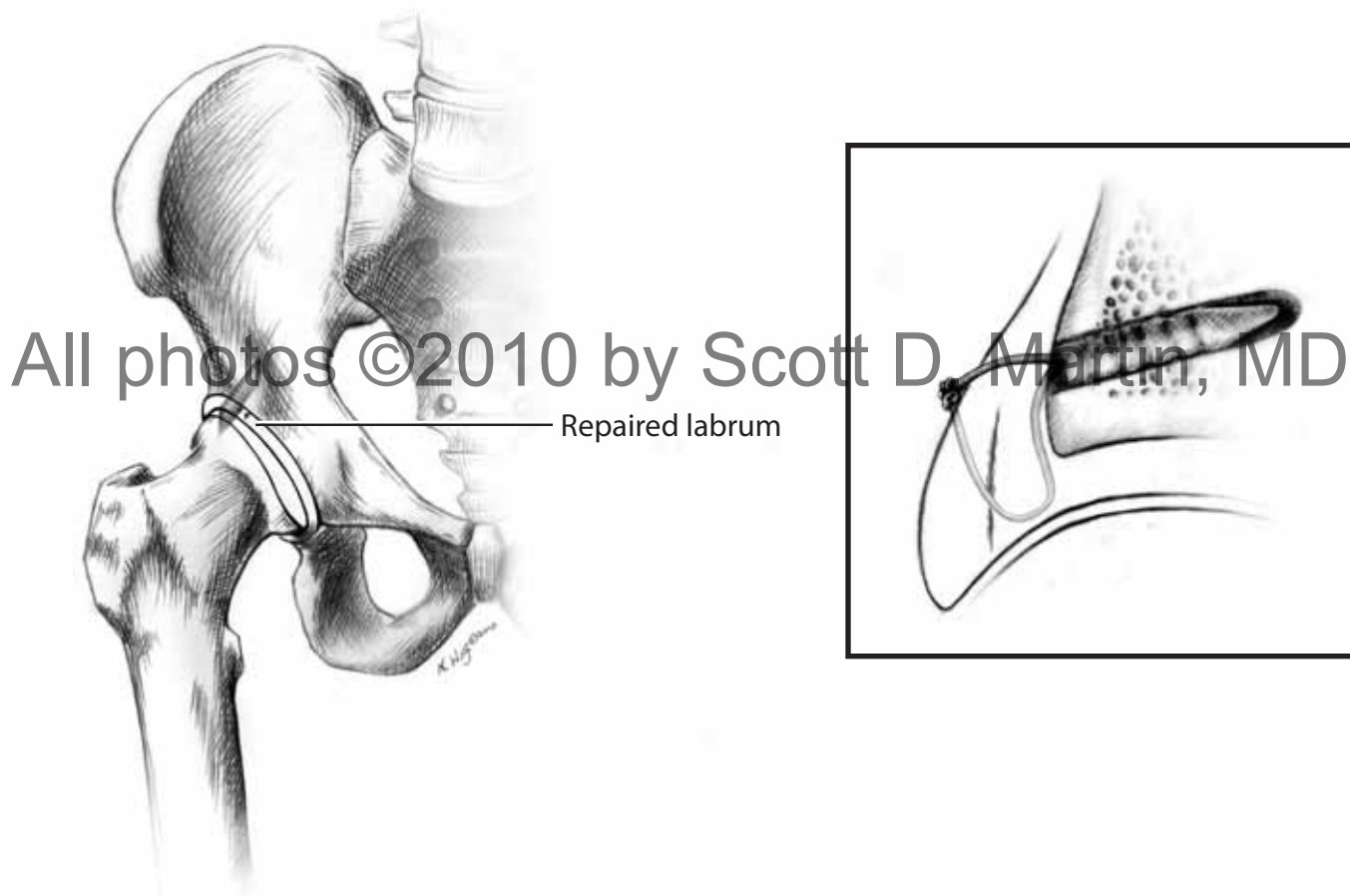


Figure 11.

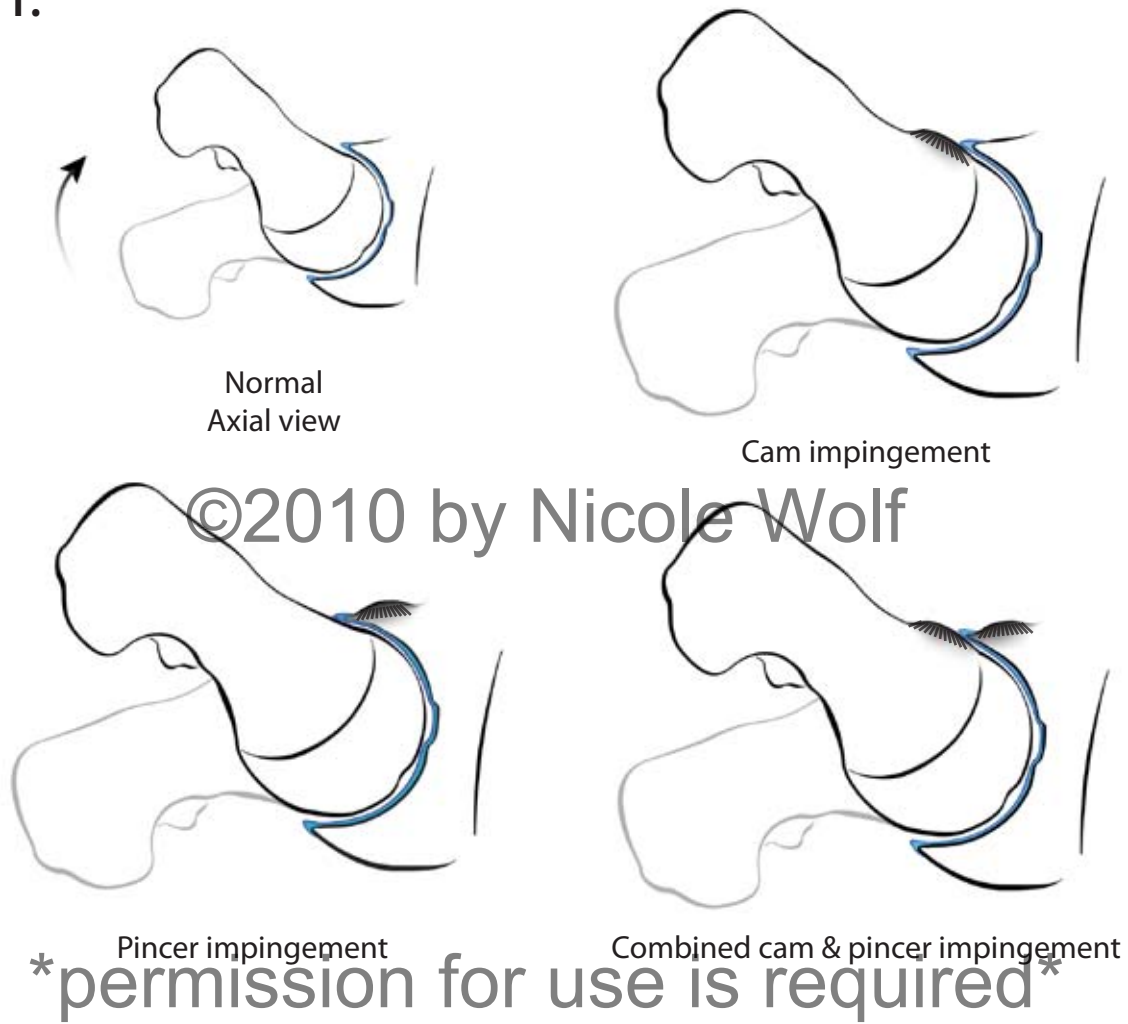


Figure 12.

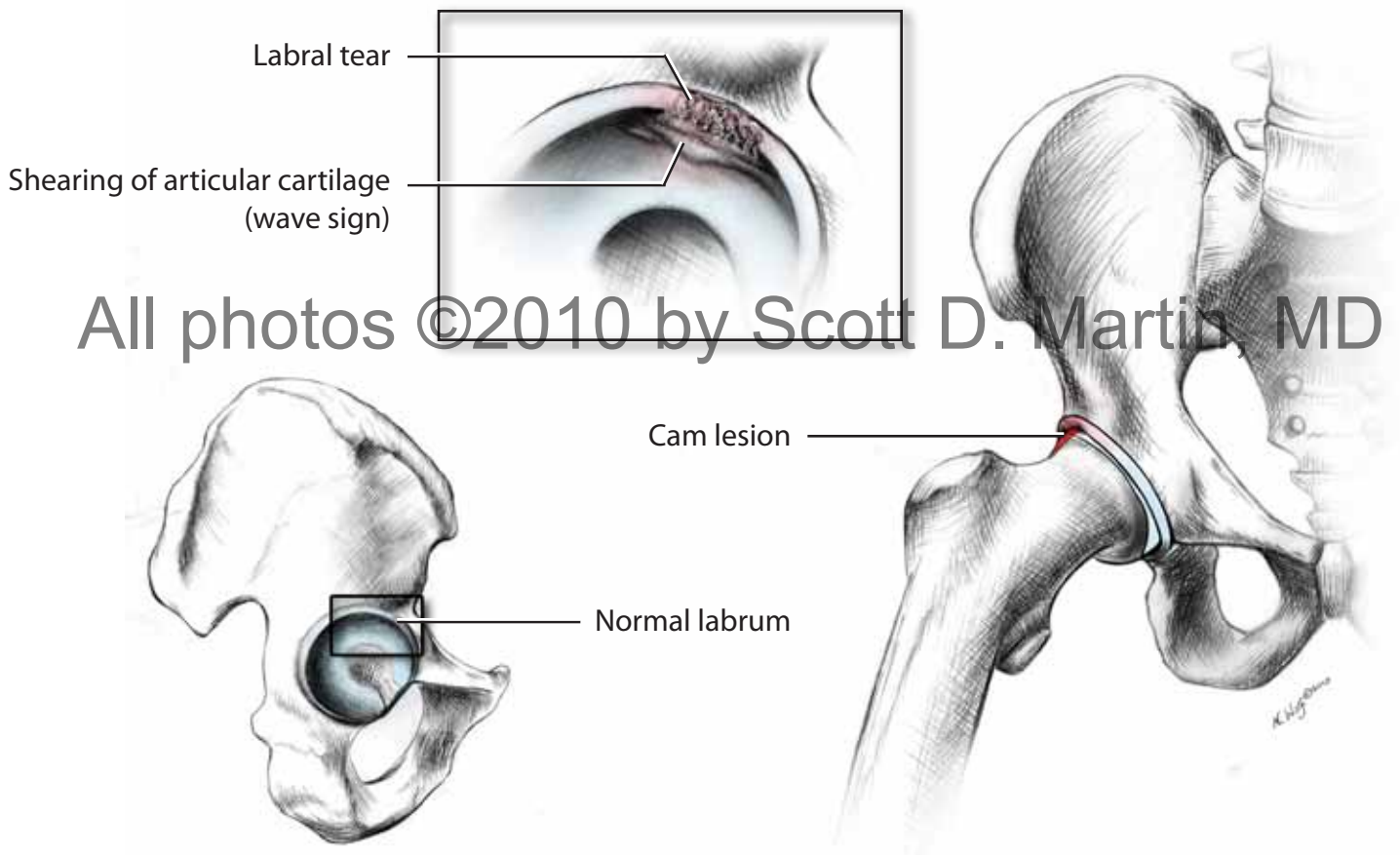
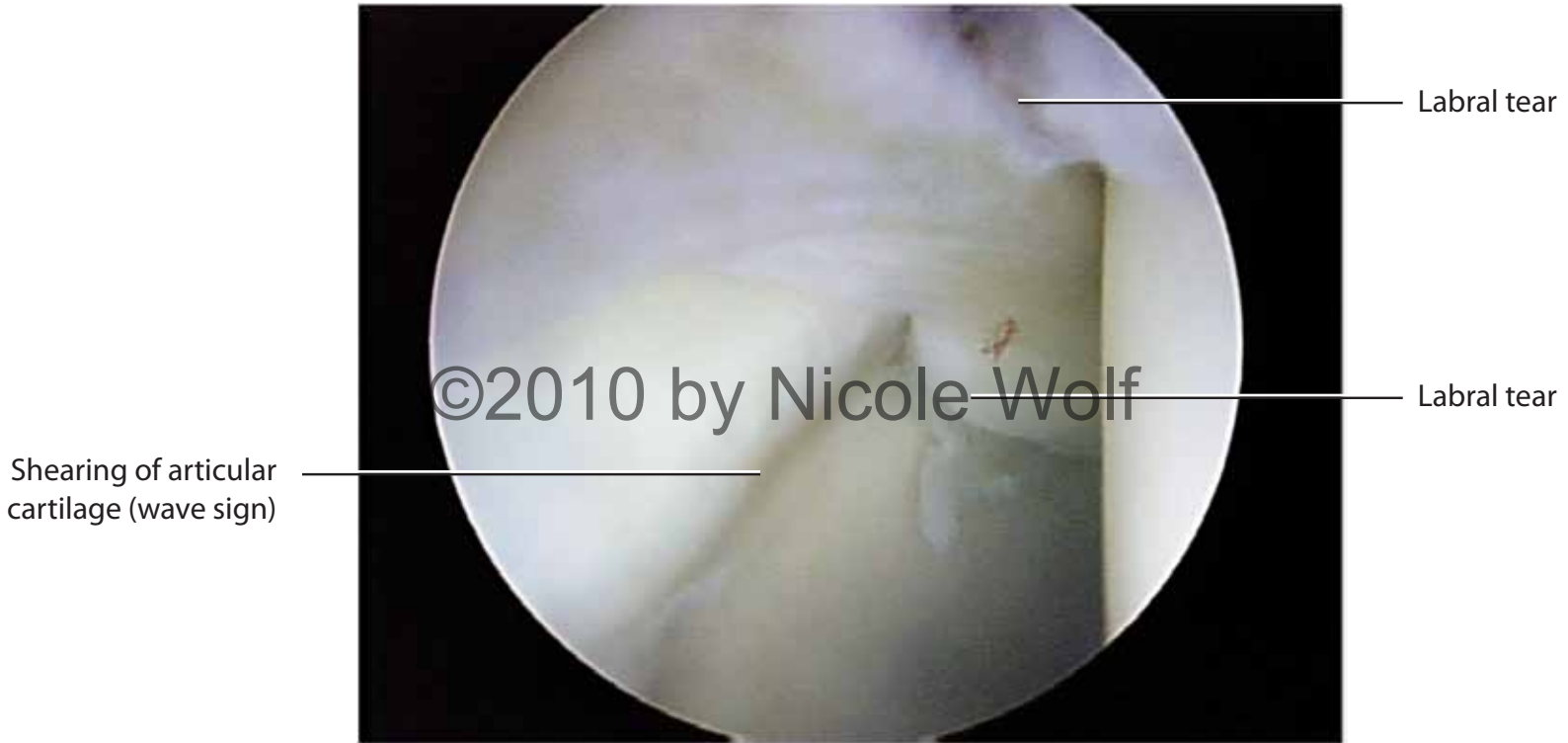

Figure 13.



permission for use is required

Figure 14.

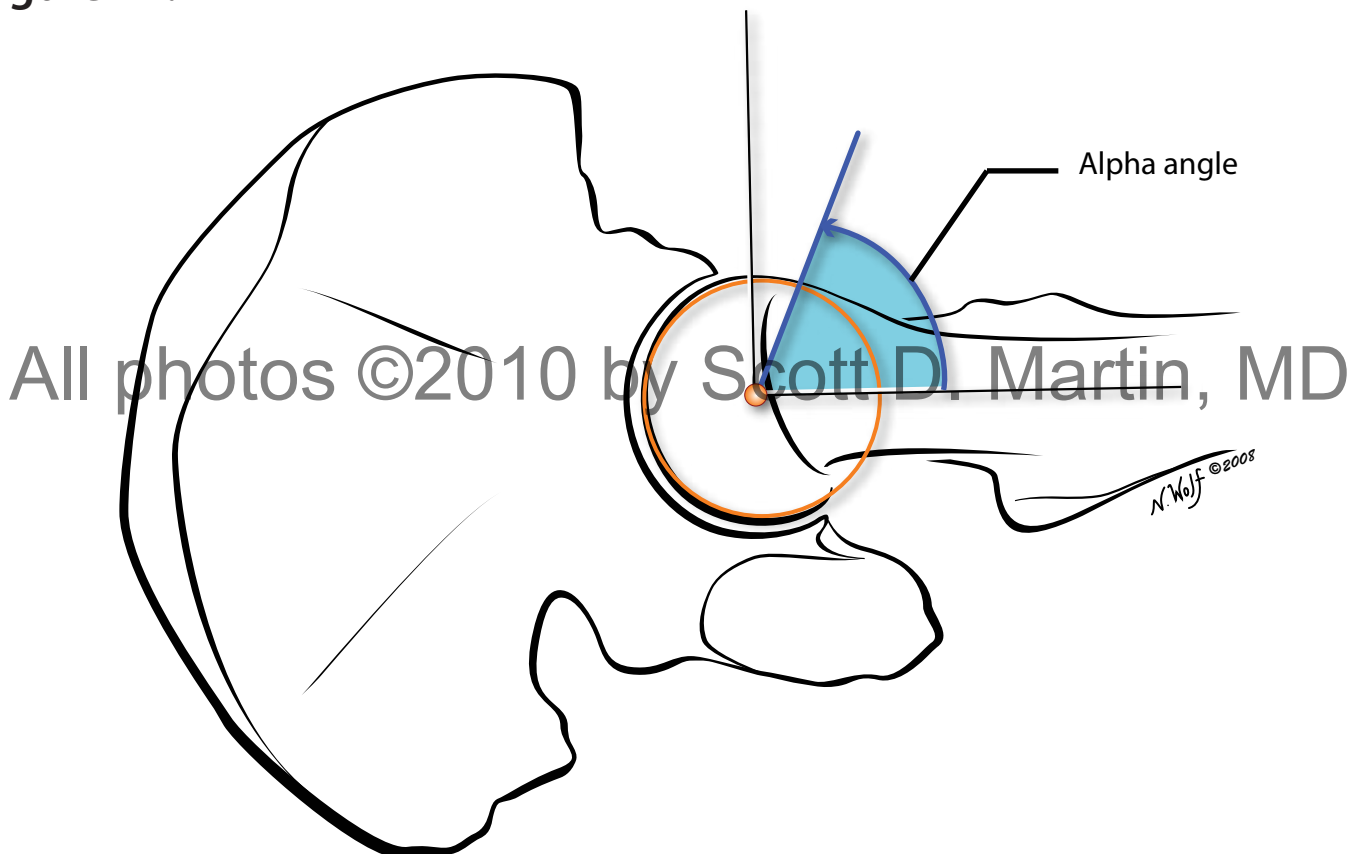


Figure 15.

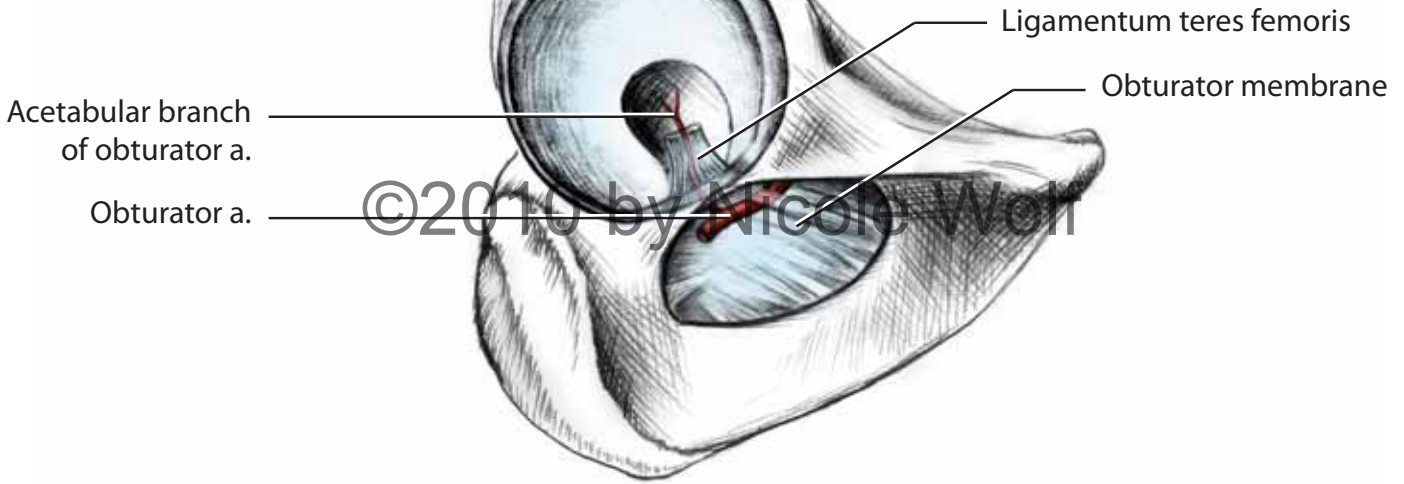


Figure 16.

permission for use is required

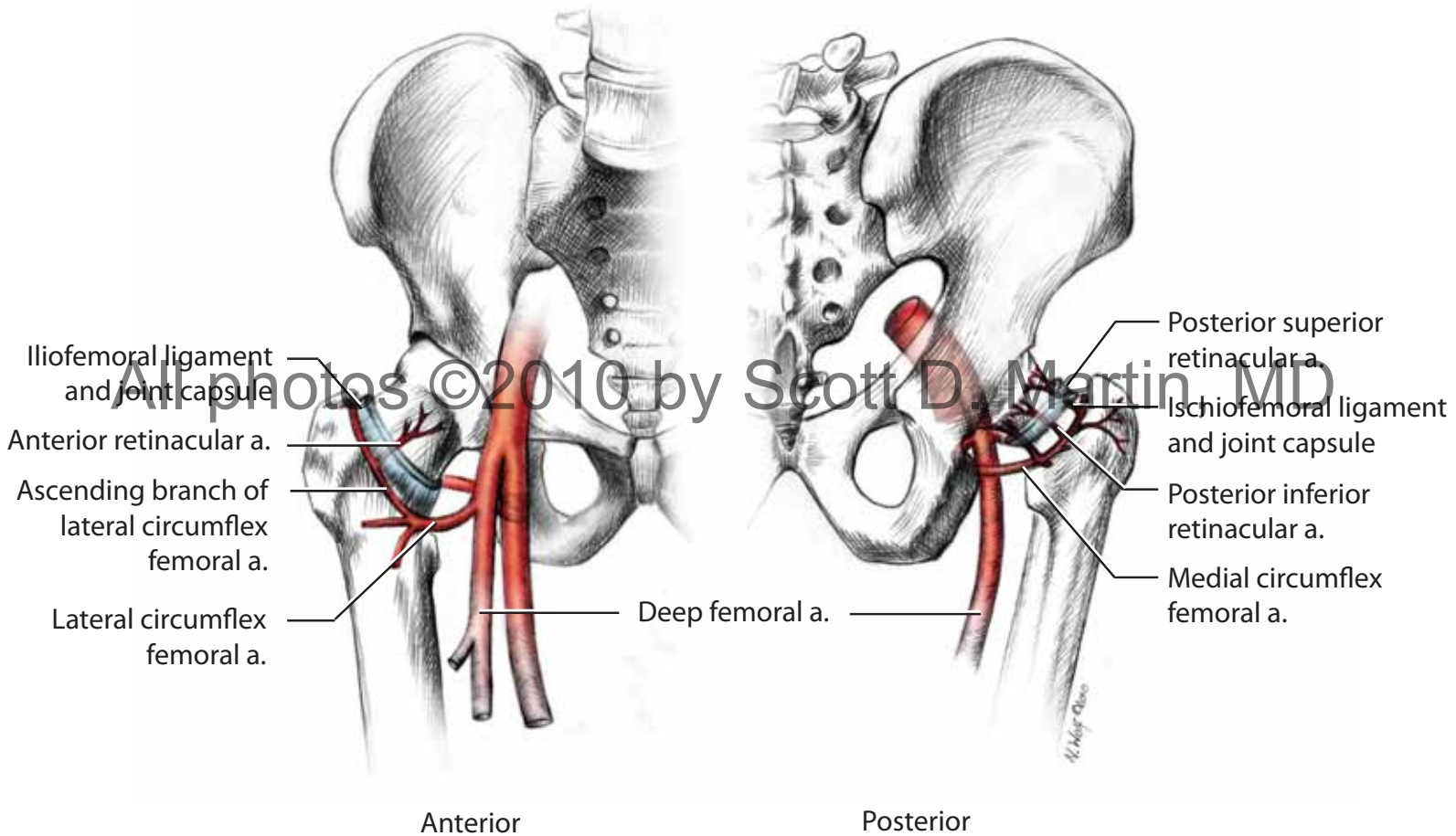
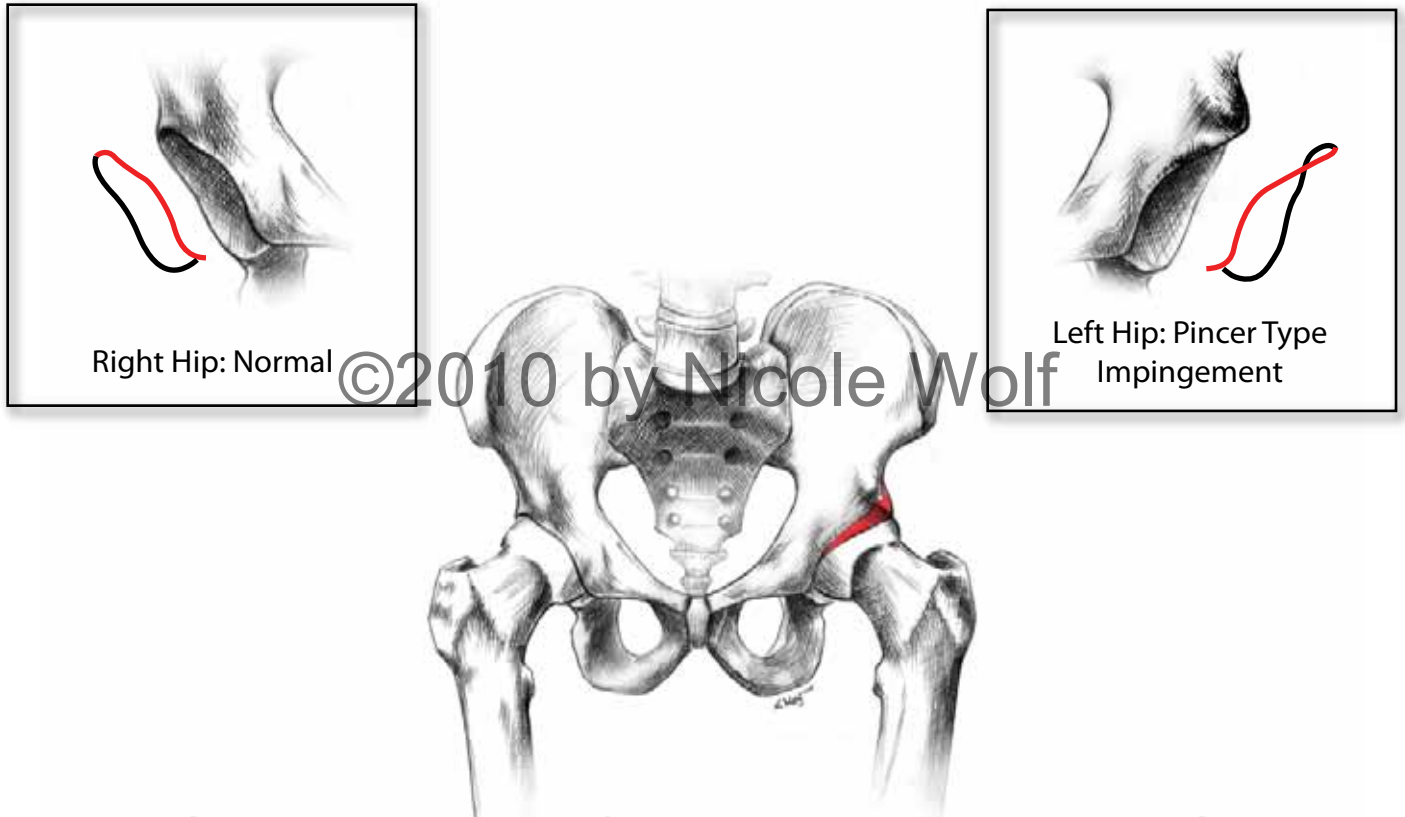
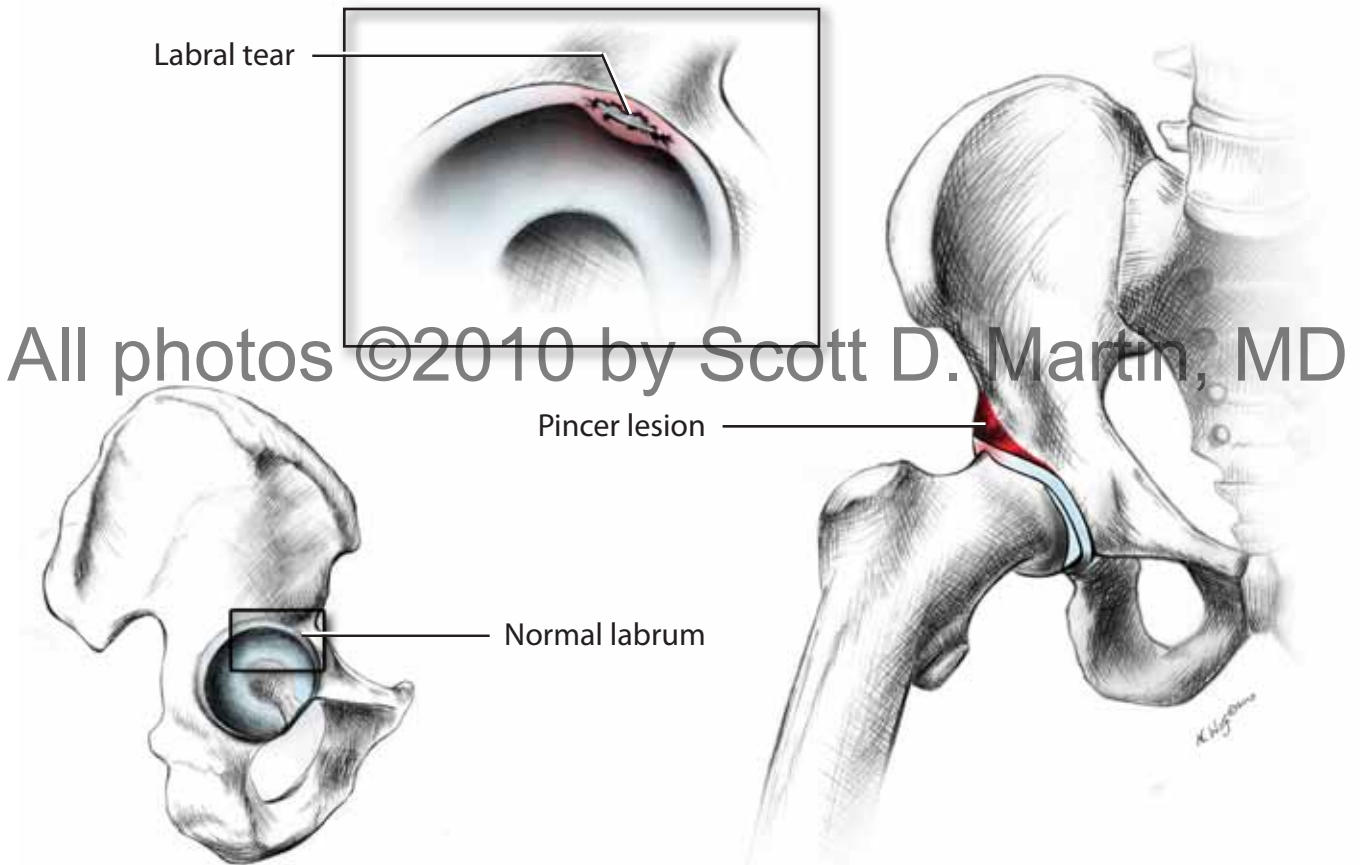


Figure 17.



permission for use is required

Figure 18.



All photos ©2010 by Scott D. Martin, MD

Figure 19.

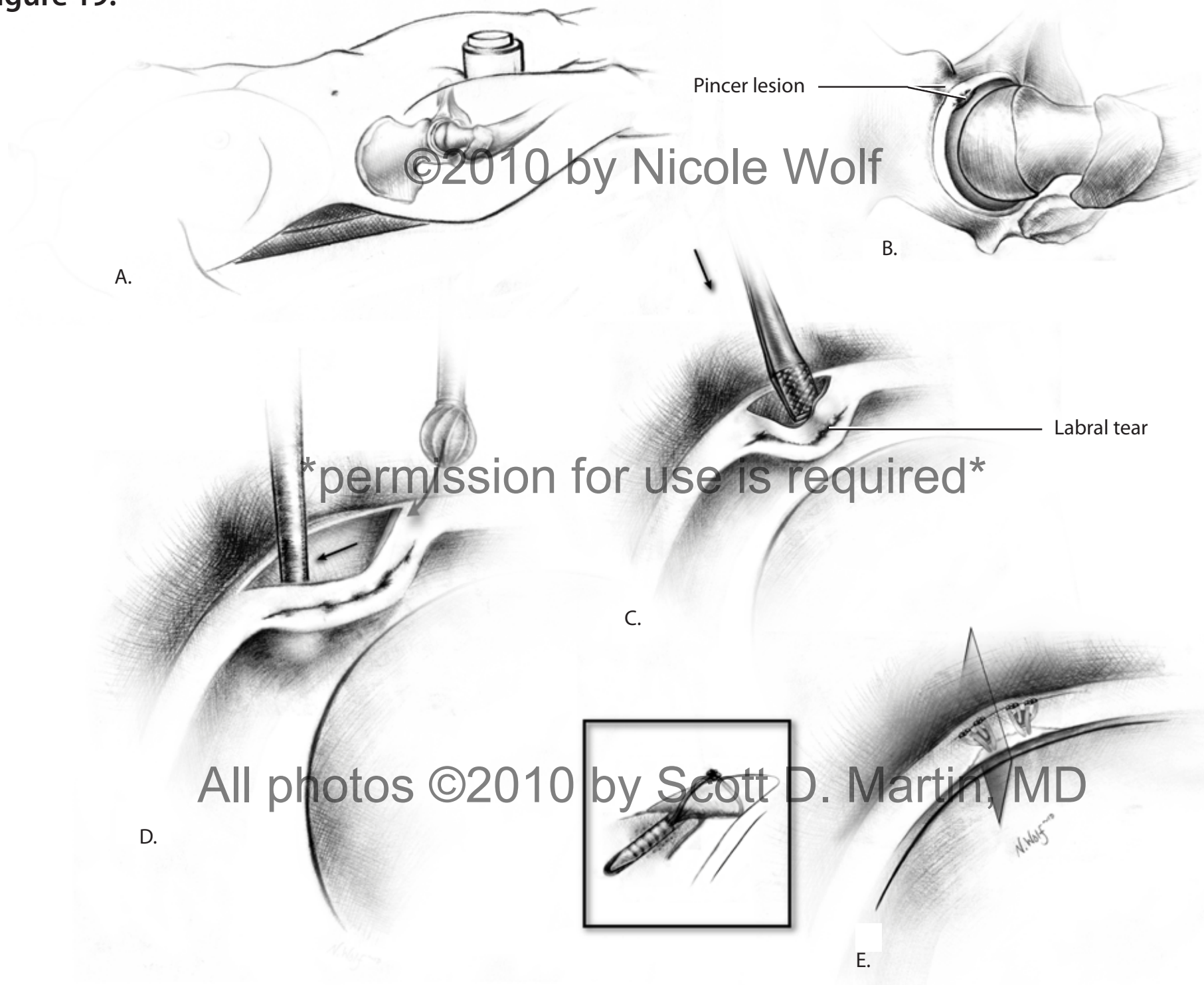


Figure 20a.



permission for use is required

Figure 20b.

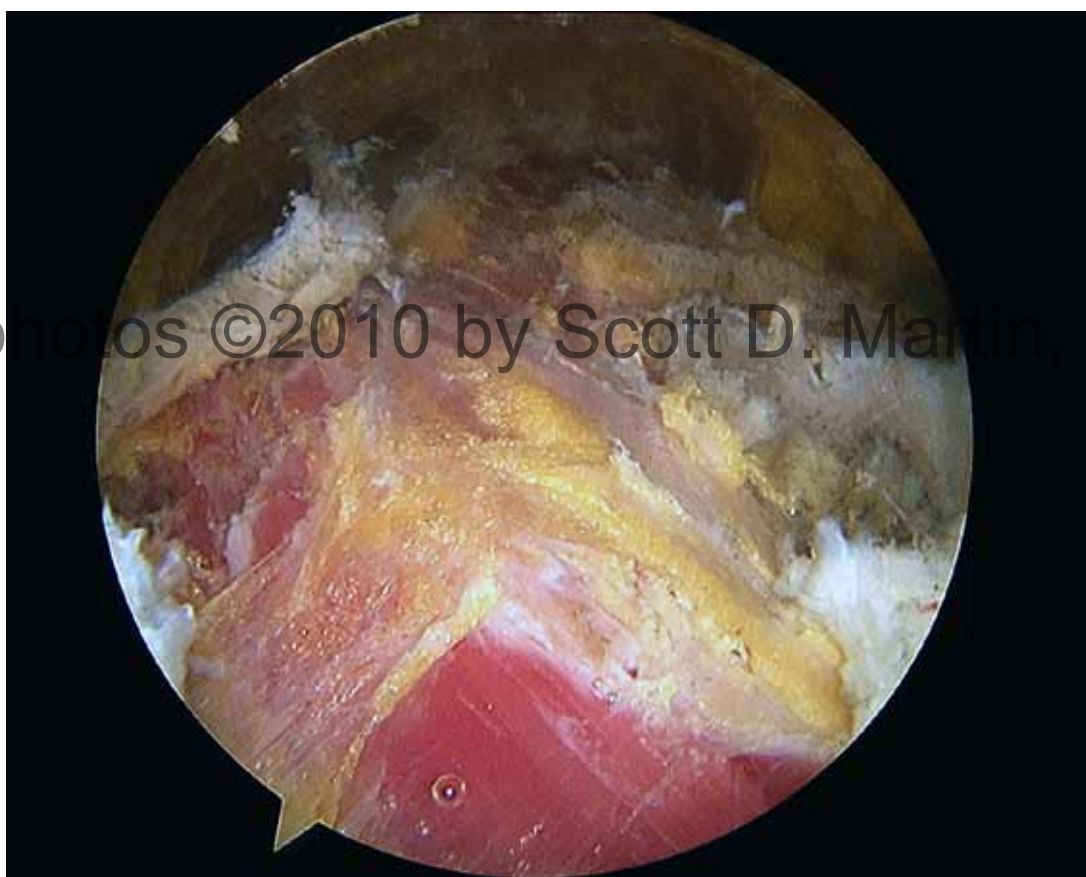

Figure 21.

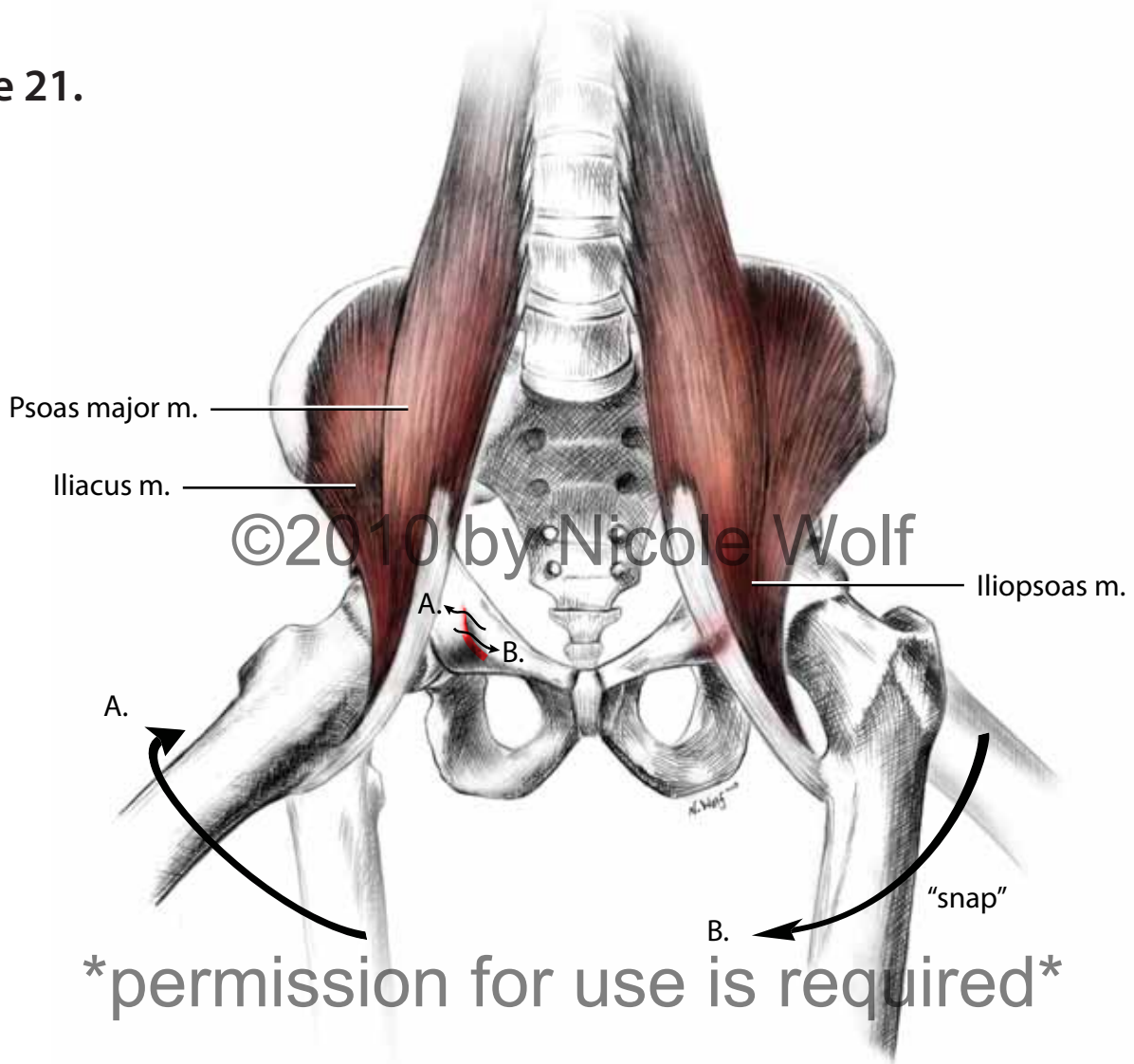


Figure 22.

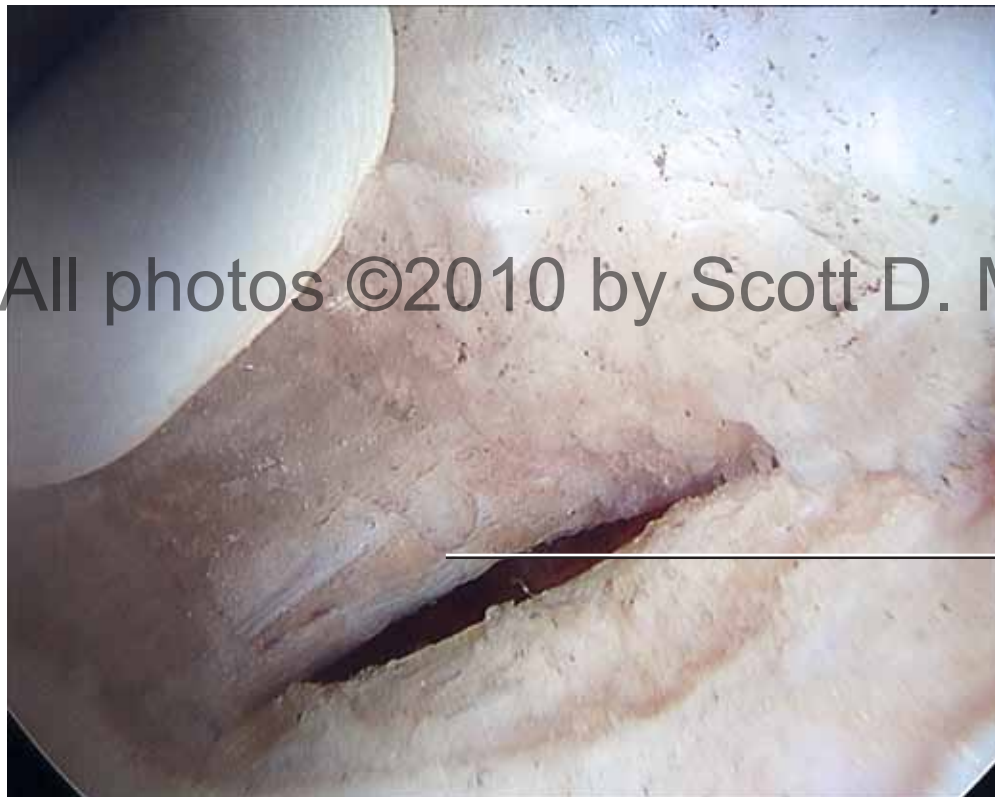

Figure 23a.

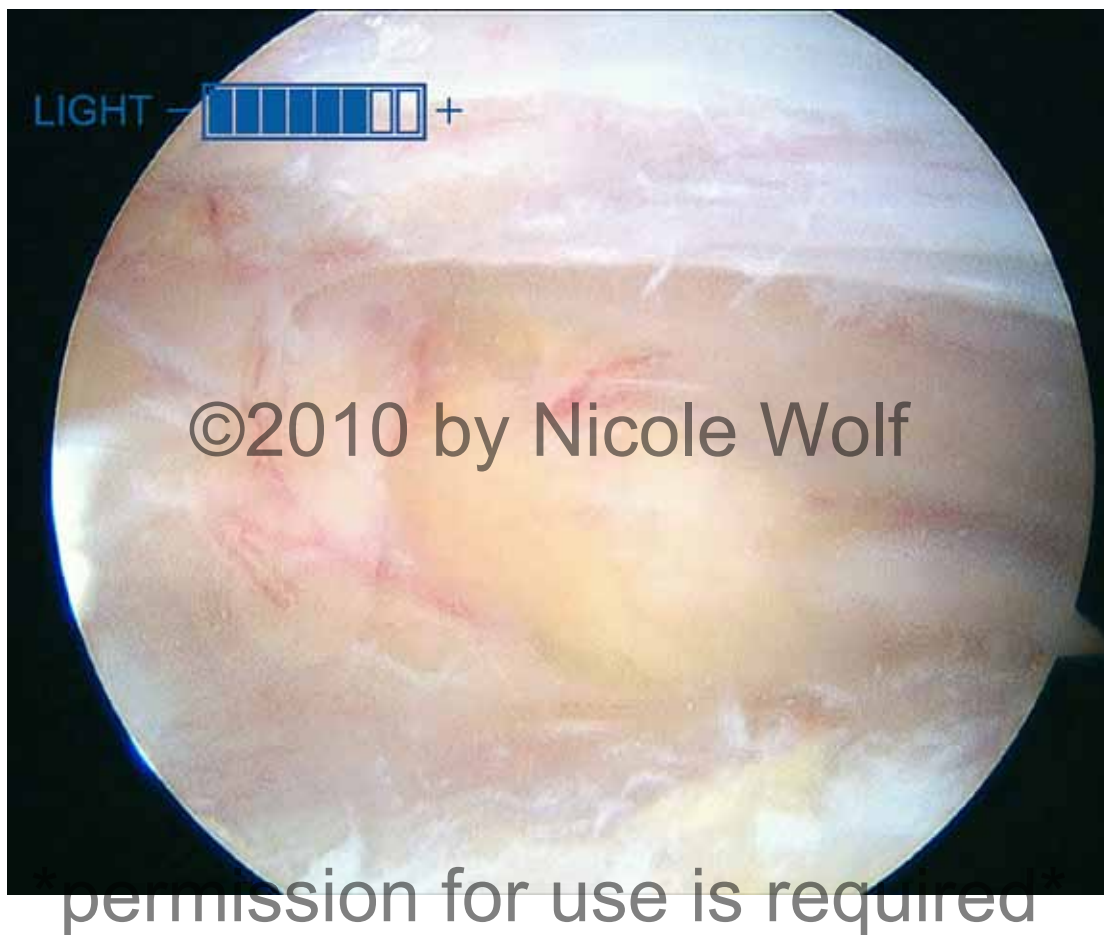

Figure 23b.

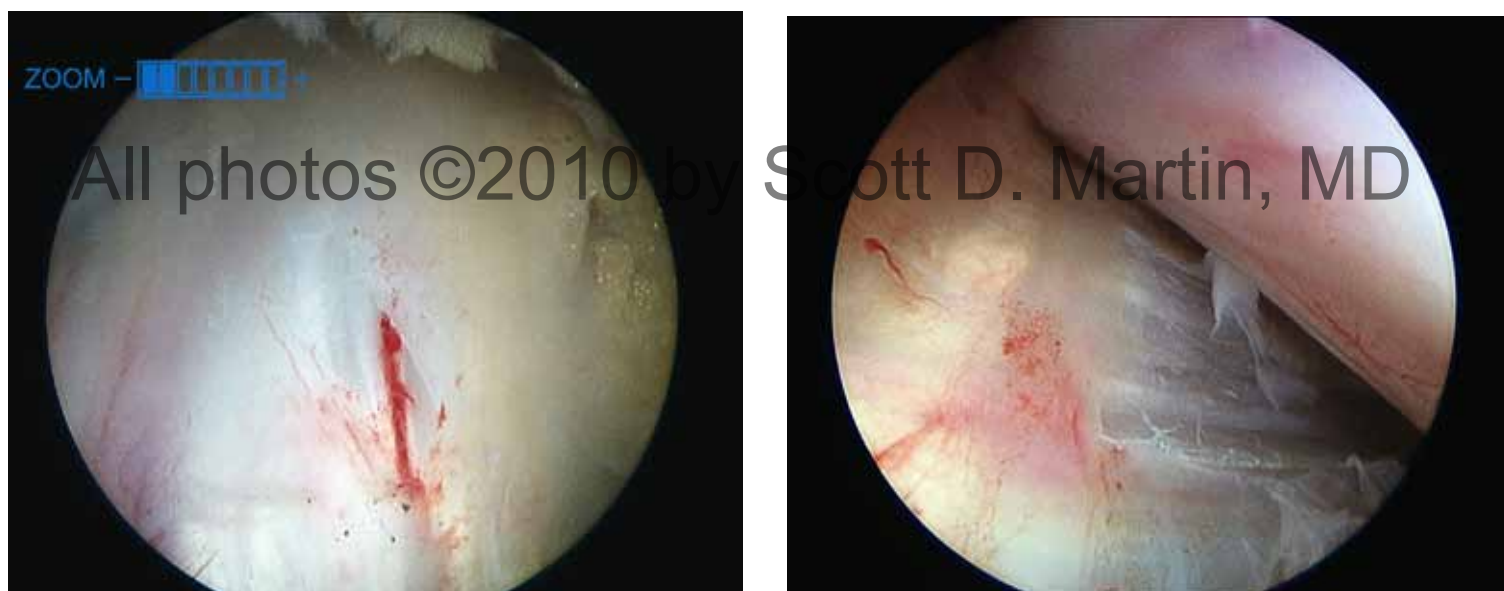
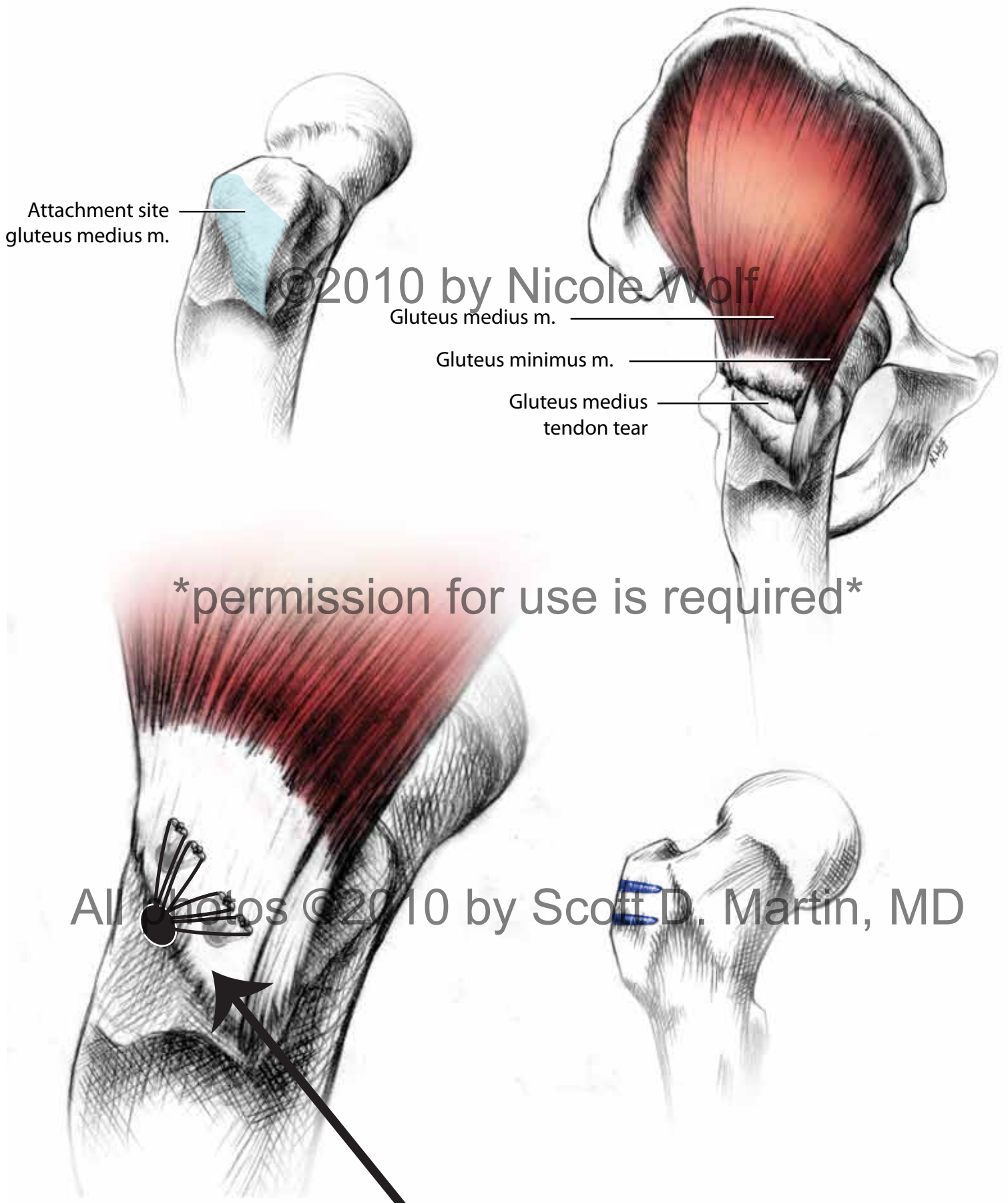


Figure 24.



IS THIS HOW THE PUSH LOCK WORKS?